Extension Folder No. 38/2010

# CASTRATION OF PIG

भाकृअनुप
ICAR

All India Coordinated Research Project on Pigs
Indian Council of Agricultural Research
ICAR Research Complex for Goa
ELA, OLD GOA, GOA 403 402

## What is castration

Surgical removal of testis or inactivation of testis function is known as castration.

## why castration is done

Castration of meat producing male animals has been widely used for a very long time, for a number of reasons including an easier control of their behaviour and the higher propensity of castrates to deposit fat, a commodity that has been in high demand until quite recently Castration in pigs is undertaken to reduce the boar taint of the pork. Although intact boars are more efficient in feed conversion and produce a leaner carcass than surgical castrates, the existence of boar taint in fat has substantially reduced the acceptance of the boar meat. Increased interest in meat production from uncastrated males is related to the declining demand for animal fat, the increased emphasis on more efficient red meat production, and the need for greater amounts of animal protein for our increasing world population. In addition, the discovery that 5-androst-16-ene-3-one is responsible for sex odour in cooked boar meat, has stimulated interest in masking or altering the objectionable meat quality characteristics of boars. To prevent boar taint, the present practice is to castrate all male pigs surgically. Boar taint is a urine- or perspiration-like odour found in pork of un-castrated pigs. Compounds responsible for boar taint include skatole, a product of tryptophan breakdown in the gut and testicular 16-androstene steroids mainly androstenone (5a-androst-16-ene-3-one). Castration also makes animal docile and enhances the body weight gain.

Removal of gonads in female i.e. ovaries is also undertaken by some of pig owners. However, it is not required as pork from females do not have boar taint.

## Age of castration

As per report from European countries and as per practices in Norway piglets are castrated at average age of ten days and at maximum age of 21 days. For practical purpose in India keeping in view the size and weight of local and crossbreed piglets male pigs should be castrated surgically at the age of 30 to 45 days and maximum of 60 days. As age increases more adhesions will be established in the scrotal pouch and testis, leading to more bleeding and risk of shock.

## Steps of castration

### 1. Preparation of animal

Male pigs should be castrated in the cool morning time. Overnight fasting is preferable to avoid spoilage of operation site by defecation. The Piglet should be cleaned, properly restrained and taken to operation table**(Fig. 1)**. Place where castration is to be performed should be clean and sterile to reduce the infection and post operative complications.

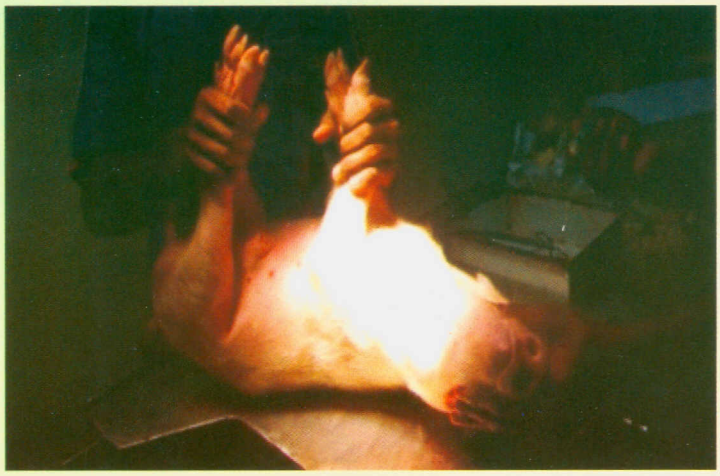

### 2. Preparation of site

Wipe the perennial area and scrotum with antiseptic solution for sterilization (Fig.2). Clip

out the long hairs, press the scrotum and fix the testicles. Apply antiseptic solutions i.e. spirit or tincture of iodine.

## 3. Application of anaesthesia

A combination of subcutaneous and intratesticular administration most often represent an improvement in animal welfare.For normal response to both handling and pain anaesthesia is better choice. Inject1.5 to 2ml of local anaesthesia i.e. lignocane hydrochloride (2%) subcutaneously along the length of the both testicles. Anaesthetic effect will be developed in 5 minutes **(Fig. 3)**

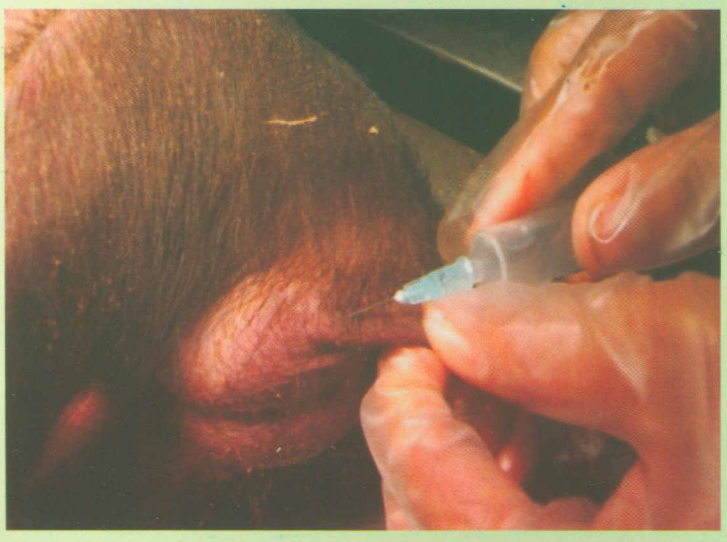

## 4. Removal of testicles and control of bleeding

a. Press the scrotum and fix one of the testicle and give longitudinal cut with BP surgical blade (No. 11). Incision of about 1 inch length is to be made and extend it depending on size of the testicle. After cutting through the skin, facial layer tunica virginalis layer will be visible which is a thin layer. **(Fig. 4)**

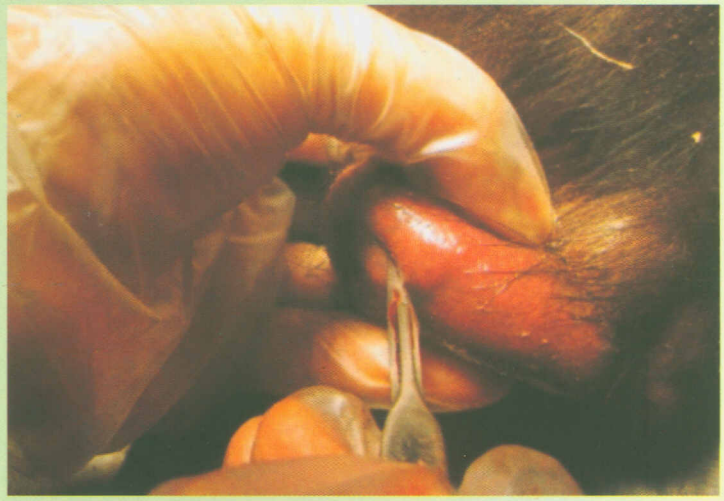

b. Gently take out the testicle after cutting the tunica vaginalis layer. Pull testicle slightly outside. (Fig. 5)

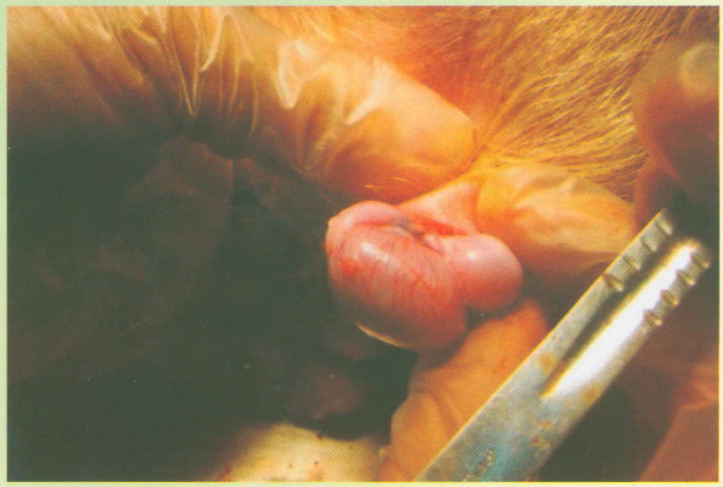

c. Separate spermatic chord and blood vessels and ligate with absorbable suture material like catgut No.1 to stop bleeding (Fig. 6 and 7,).

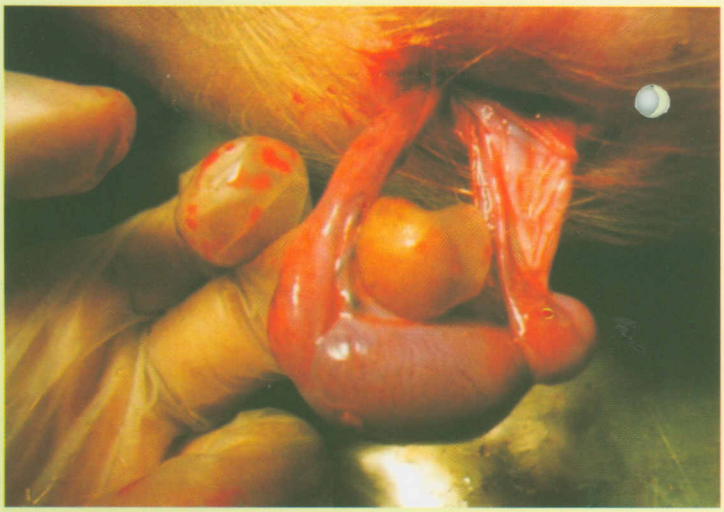

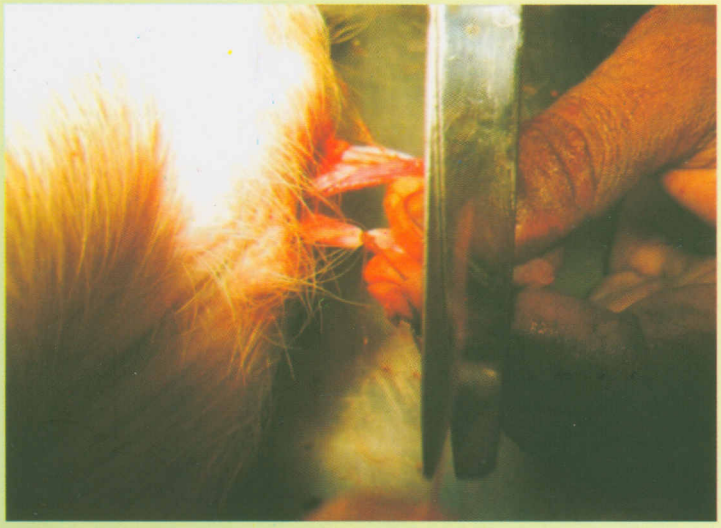

## 5. Removal of testicles

Cut the spermatic chord and blood vessels below the ligation and remove the testicls (Fig 8 and 9)

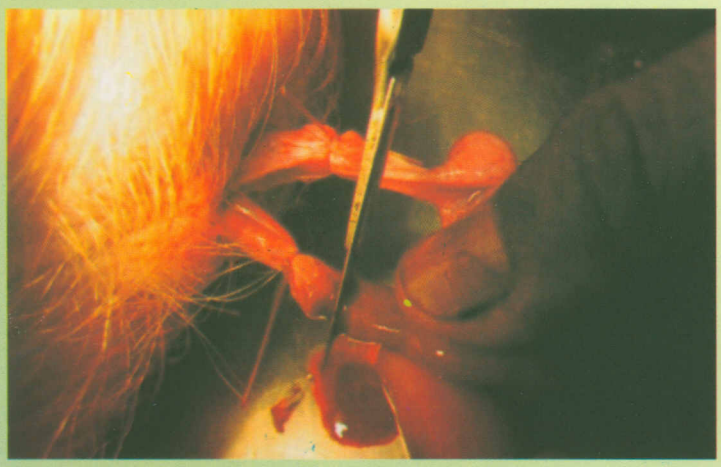

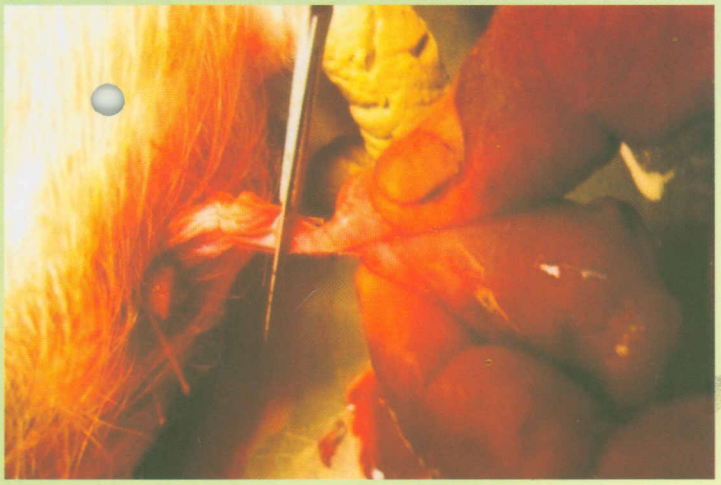

## 6. Dressing of wound

Now treat the wound as open wound (Fig. 10). Flush surgicle wound with antiseptic solution (Fig. 11) and powder (Fig. 12) and inject antibiotic (Fig. 13)

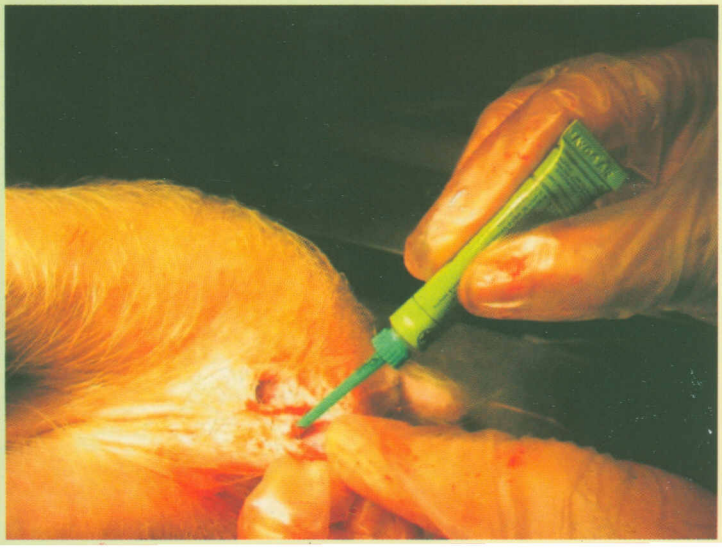

**7. Observe the animal at least for three days for any surgical complication if any**


**Prepared by**

**DR. E. B. CHAKURKAR**
Senior Scientist
(Animal Reproduction)

**DR. P. K. NAIK**
Senior Scientist
(Animal Nutrition)

**DR. B. K. SWAIN**
Senior Scientist
(Poultry Science)



**Published by**

**DR. N. P. SINGH**
Director, ICAR Research Complex for Goa,
Ela, Old Goa, Goa 403 402



**For details please contact**

**DR. N. P. SINGH**
Director, ICAR Research Complex for Goa,
Ela, Old Goa, Goa 403 402
Telephone: 0832-2284678/79
E-mail: director@icargoa.res.in
Website: www.icargoa.res.in





**Technical Assistance**
**Mr. Edward Crasta**

**Designing**
**Mr. Sidharth Marathe**